

RESEARCHES ON HYPOPHYSIS OF SILVER CARP FEMALE BREEDERS IN THE FISH FARM CARJA I (THE VASLUI COUNTY) IN VITELLOGENETIC GROWTH PERIOD

A. SIRBU (POPESCU)*, M. FETEAU, V. CRISTEA, M. T. COADA

Faculty of Food Science and Engineering, 'Dunarea de Jos' University of Galati, 61–63 Garii Street, 800 008 Galati, Romania

E-mail: adina.popescu@ugal.ro

Abstract. The presented paper wishes to underline the importance of sampling period of the silver carp hypophysis used for hypophisation in artificial reproduction. Our researches have focused on hypophysis structure modifications in special of the middle gonadotrop lobe in parallel with the ova evolution of the sexual mature carp females in their development stages and vitellogenesis period. The histological analysis of the ova in this time has emphasised the following evolution of the sexual cell of the carp females: at the end of the November 2007, predominant are oocytes in the stage VII^A with a diameter of 940–1000 μm ; at the beginning of the April 2004, predominant are oocytes in the stage VII^A with a diameter of 1000–1100 μm . In the purpose of chasing the hypophysis activity in parallel with sexual ova cells evolution, we have analysed in the same period the hypophysis structure from the various females with the same age. The middle lob contains two types of cells: the STH acidophil cells which secret the hypophysis somatotrop hormone, stimulating the growing the cells but not least GTH cells which secret gonadotrop, one of them seems to become chromophobe.

Keywords: hypophysis, oocyte, hormone, chromophob, gonadotrop.

AIMS AND BACKGROUND

Considering the scientific and practical importance of the hypophysis hormones in inducing of fish gonad maturation we have considered effective histological study on the hypophysis and on the ova in vitellogenetic growth period in order to observe concomitant evolution of the secretive cells and of the ova. We can draw conclusions regarding the optimum period for the hypophysis harvest used for the injection with hypophysis for artificial reproduction.

H. molitrix oogenesis includes like in other teleosten fishes the following distinct periods: multiplication or oogonial period, growth (previtellogenesis, slow or protoplasmic growth and vitellogenesis, fast growth or trophoplasmatic growth) and maturation¹.

During the multiplication period occur successive mitotic divisions resulting in a pool of sexual cells². Polycyclic species as is the case of our specimens, from

* For correspondence.

reserve of previtellogenetic oocytes will result the oocytes generation that develops into the final stages, the recruitment of the reserve stock of vitellogenic oocytes taking place continuously.

Researches conducted by different authors in some species of cyprinids (*Cyprinus carpio* and *Carassius auratus*) have shown that before reaching sexual maturity, the cells responsible for producing basophils gonadotropic hormone GTH present different aspects of development. In the first phase of secretion, granules contain small, rare and well-developed Golgi apparatus and a most advanced stage of development. Cells contain two types of grains: some are similar to that of the previous stage, while others are large granules³. This corresponds to gonadotropic hormone accumulation in the cytoplasm.

The presence of secretory cells of gonadotropic hormones and gonadal stage of development of the female of *H. molitrix* is in correlation between them and this results from comparing the pituitary structure in the first period of reproductive cycle (vitellogenetic growth). Secretory cells content of the gonadotropic cells are cellular organelles storage of hormone secretion^{4,5}.

EXPERIMENTAL

The ova samples comes from 4–6-year old mature carp females which reproduce normally in the Carja I (the Vaslui county) farm conditions. After sampling, material was histologically adapted through classic method. The estimation of the oocyte development was made according to maturation scale for the common carp females⁶ and Asiatic cyprinids⁷.

Size measurement of the ova dimension was performed with a Zeiss ocular micrometer and the micropictures were obtained using a Carl Zeiss microscope, Axio Imager A1 model with Canon camera, 10 mega pixels, 4× optical zoom.

RESULTS AND DISCUSSION

The environmental conditions in the fish farm Carja I (the Vaslui county), in our research during winter (November 2007 – April 2008) on silver carp oocytes undergo the vitellogenetic growth period. During this period (November 2007–April 2008), on histological sections it is noted primarily asynchronous oocytes development. Characteristic, for the months of November–December 2007 (carp ovaries from 4–5-year old of average weight 5 kg), is the fact that most oocytes in ovaries are in the VII^A stage, with dimensions ranging from 940 to 1000 μm (Fig. 1). In cytoplasm, cortical vesicles are pushed to the oocyte periphery (to its membrane) by vitellus plackets (Fig. 2). In the VII^A stage, the oocytes go through the winter, their increase in size towards the end of winter is due to the trophoplasmatic growth resulting in the accumulation in the cytoplasm of vitellus.

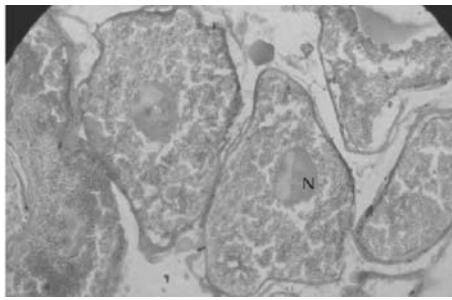


Fig. 1. Section through mature ovary of silver carp, VII^A stage (November–December 2007), Ø = 940–1000 µm (can be observed centrally located nucleus, coloration hemalaun–eosin, objective 10)

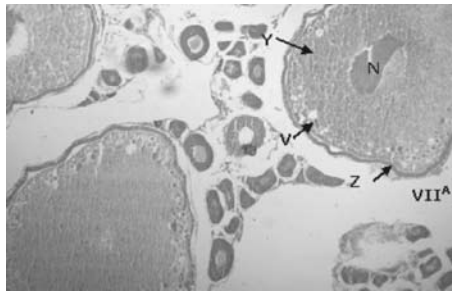


Fig. 2. Section through mature ovary of silver carp, VII^A stage (November–December 2007), the cortical vesicles are pushed to the oocyte periphery by vitellus plackets and centrally located nucleus contains nucleolus detached from the nuclear membrane and previtellogenetic young oocytes (coloration hemalaun–eosin, objective 10)

The sections can be seen in less advanced oocytes (V and IV^B stages), with varying sizes, ranging from 218 to 500 µm, in the beginning of the vitellogenesis.

In late March and early April 2008 silver carp 5–6-year old with average weight 6 kg predominates in the previous period from VII^A stage oocytes (Fig. 3*a*), but in larger 1000–1100 µm, are growing accumulation of nutrient vitellus. These oocytes are in the latest phase of vitellogenesis process. Thus, vitellus plackets are larger and so the mucopolisaccharide cortical vesicles and radiated area become dense surrounding the oocyte. The nucleus is centrally located. Oocytes are present at all other stages VI–I (Fig. 3*b*, *c* and *d*).

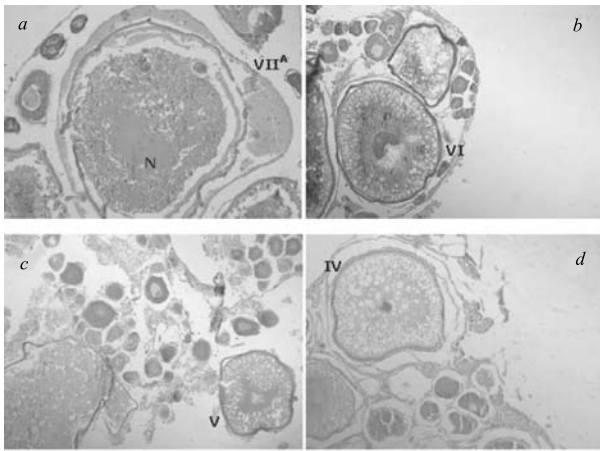


Fig. 3. Mature oocyte, VII^A stage (a) (April 2008) phase of the vitellogenesis process (1000–1100 mm), follicular shells are thicker. At this stage oocytes are present in all other stages VI–I (b, c, d); coloration hemalaun–eosin (a, c, d) and azan (b) (objective 10)

During this period the histology performed on pituitary sections taken from mature females of *H. molitrix* from November to April in the middle gonadotrop lobe (*pars distalis proximalis* – PPD) shows predominate basophils glycoprotein gonadotropic cells. They have an eccentric nucleus and the cytoplasm is stained with heavily loaded grains, suggesting a hormonal storage (Figs 4–7). It is noted gradual loading of cells with granules of hormonal secretion in the winter period suggesting a high secretory activity of the pituitary.

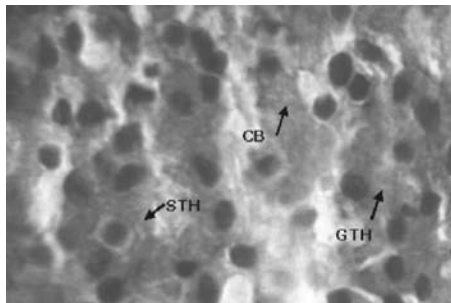


Fig. 4. Middle gonadotrop lobe (PPD): GtH cells arranged in cords among rare STH cells and chromophobe cells (CB) (coloration hemalaun–eosin, objective 90)

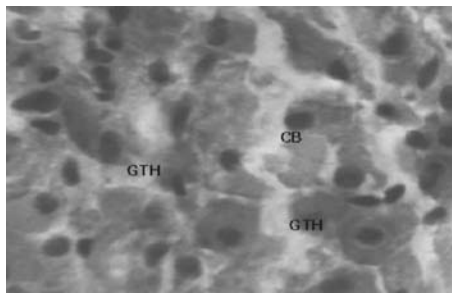


Fig. 5. Middle gonadotrop lobe (PPD): GtH cells with elongated or round eccentric nucleus, among these chromophobe cells (CB) whose cytoplasm not stained (coloration hemalaun–eosin, objective 90)

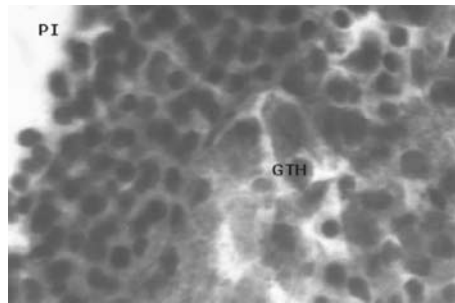


Fig. 6. Middle gonadotrop lobe (PPD): GtH cells (coloration hemalaun–eosin, objective 90)




Fig. 7. Middle gonadotrop lobe (PPD): GtH cells ending on nerve fibres. The number is smaller in this area (coloration hemalaun–eosin, objective 90)

This leads to an important conclusion for hormonal induction in aquaculture practice: to remove the pituitary of sexually mature females for the pituitary injections before the reproduction season (December–April), the period during which it accumulates in pituitary the largest amount of gonadotropic hormones, released in spring, the period of the maturation process of oocytes. In the middle gonadotrop lobe (PPD) can be observed acidophil somatotrop cells (STH) which are smaller and with fine grains.

CONCLUSIONS

The histological analysis performed by us on the ovaries of mature female carp, revealed that in the studied period the development of oocytes was carried out normally in the Carja 1 farm conditions (the Vaslui county).

In the fish farm Carja 1 conditions of our research shows that during November 2007–April 2008 oocytes of silver carp are undergoing vitellogenetic growth period. Most oocytes are in VII^A stages. Oocytes of VII^A stage have size between 940–1000 µm (November–December 2007) and in late March and early April 2008 show an increase up to 1100 µm due to vitellus nutrient accumulation. On histological sections can be observed oocytes of V and IV^B stages of various sizes ranging from 218–500 µm in the beginning of the vitellogenesis stage and oocytes from all other stages to VI–I.

In vitellogenetic period on histological sections performed from the pituitary of mature females of *H. molitrix* from November to April, the middle gonadotrop (PPD) gonadotropic basophils glycoprotein cells predominate. It is noted gradual loading of cells with granules of hormone secretion during this period, suggesting a high secretory activity of the pituitary. Hence, we can suggest an important decision for hormonal induction in aquaculture practices – removing the pituitary of sexually mature females for pituitary injections during winter. The season before reproduction (November–April) is the period which has accumulated the largest amount of pituitary gonadotropic hormones and this amount is released during oocytes maturation.

Acknowledgements. Researches were conducted in the framework of the project POSDRU No 6/1.5/S/15 ‘Efficiency of Ph. D. Students Activity in Doctoral Schools No 61445 – EFFICIENT’, funded by the European Union and the Romanian government. The authors thank the management staff of the project for their support.

REFERENCES

1. A. P. MAKEYEVA: Embryology of Fishes. Moscow University, Moscow, 1992.
2. H. TAKASKI: Fish Histology. Guctav Fischer Verlag, Stuttgart, 1982.
3. P. MELARMED, N. SHERWOOD: Hormones and Their Receptors in Fish Reproduction. Molecular Aspects of Fish and Marine Biology. Vol. 4. World Scientific Publishing Co. Pte. Ltd., London, 2005.
4. T. Y. WILLIAM, H. W. JOSEPH: Microscopic Anatomy of Salmonids. Washigton, 1983.
5. H. EVANS: The Physiology of Fishes. 3rd ed. (Marine Biology). CRC Press, 2006.
6. I. STEOPOE, A. NICOLAU, A. CRISTIAN: Contributions to the Study of Carp Ovarian Cycle and Gonadal Development. Bulletin I.C.P. P. Bucharest, **17** (3), 28 (1967).
7. A. NICOLAU, I. STEOPOE: Oogenesis of Phytophagus Fish (*Ctenopharyngodon idella*, *Hypophthalmichthys molitrix* and *Aristichthys nobilis*) in Controlled Growth Conditions in Romanian Waters. Bulletin I.C.P. P. Bucharest, **24** (3), 5 (1970).

Received 27 May 2011

Revised 18 July 2011